



Revista Española de Cirugía Oral y Maxilofacial

versión impresa ISSN 1130-0558

Rev Esp Cirug Oral y Maxilofac v.29 n.4 Madrid jul.-ago. 2007

doi: 10.4321/S1130-05582007000400005

ARTÍCULO CLÍNICO

Guided bone regeneration using aluminum oxidemembrane in combination with osseointegrated implants

Regeneración ósea guiada utilizando membranade óxido de aluminio en combinación con implantes oseointegrados

M. Isa Majluf¹, J. Harán Vega², G. Moreno Zárate³

1 Profesor Asistente, Departamento de Cirugía y Traumatología Maxilo-Facial.

2 Cirujano Dentista.

3 Profesor del Departamento de Radiología.

Universidad de Chile, Santiago de Chile, Chile

[Correspondence](#)

Servicios

- Servicios personalizados
- Artículo en PDF
- Artículo en XML
- Referencias del artículo
- Como citar este artículo
- Accesos
- Citado por SciELO
- Citado por Google
- Similares en SciELO
- Similares en Google
- Traducción automática
- Enviar artículo por email

ABSTRACT

Alveolarbone loss has been a very important cause of complications in osseointegratedimplant rehabilitation of edentulous patients. This paper evaluates theeffectiveness of aluminum oxide membrane (Allumina) in the collapsed alveolarridge where implants were used. Seven sites were studied in 5 patients. In eachof these sites a HIS implant plus a non-biodegradable oxide aluminum membrane (Allumina[®]),was placed for 14 weeks. All patients were treated with the same surgicalprotocol. The average gain (in mm) obtained in decreasing order was as follows:ANM: 1.7 mm, ANME: 1.6 mm, AND: 1.1mm, AV: 1.0mm, AP: 0.5mm. The clinicalresults were radiographically verified and these showed bone neoformation, inaddition to favorable peri-implant bone density. The t-Student statisticalanalysis based on the clinical results was significant for all the parametersevaluated with the exception of AP.

Key words: Membrane; Allumina; Bony regeneration; Implant.

RESUMEN

Lareabsorción ósea de los maxilares ha sido una de las mayores complicaciones almomento de rehabilitar a pacientes con implantes oseointegrados. El siguienteestudio evaluó la efectividad de la membrana de óxido de aluminio (alúmina),en la regeneración ósea de rebordes colapsados y alvéolos en los que secolocaron implantes.

De un total de cinco pacientes seleccionados, se estudiaron siete sitios de los cuales tres correspondieron a un solo paciente. En cada sitio (alvéolo o reborde colapsado) se colocó un implante de titanio del sistema HIS y una membrana no biodegradable de óxido de aluminio (Allumina®), la cual fue retirada a las 14 semanas. Todos los pacientes fueron sometidos al mismo procedimiento quirúrgico. La ganancia promedio en mm obtenidos en orden decreciente fue la siguiente: ANM: 1.7mm, ANME: 1.6mm, AND: 1.1mm, AV: 1.0mm, AP: 0.5mm. Los resultados radiográficos ratificaron los resultados clínicos en cuanto a neoformación ósea, observándose además una favorable densidad ósea periimplantaria. El análisis estadístico (basado en los resultados clínicos) t-student fue significativo para todos los parámetros evaluados con excepción de AP.

Palabras clave: Membrana; Alúmina; Regeneración ósea; Implante.

Introduction

Alveolar bone resorption is a physiological process that can arise as a result of dental extraction.¹¹ Sufficient bone volume is considered the most important prerequisite for the long-term prognosis of implants.⁹ Numerous authors have carried out studies with a large quantity of graft and membrane material with the aim of improving the condition of the ridge, and also in cases of dehiscence when placing the implant. These biomaterials have been used independently and together, and different degrees of success have been achieved.¹⁸ Most of the membranes used in guided bone regeneration require a filling material for avoiding collapse.

In 1999 Isa and col. used aluminum oxide membrane for preserving the alveolar ridge after the extraction of lower third molars without graft material, and they obtained excellent results.²⁵ Petersen and cols. used these same aluminum membranes for treating type II fork branches in humans with excellent results.²⁸ This study provides our results with aluminum oxide membranes for improving the condition of the alveolar ridge in which implants were installed, without using graft material.

Material and method

Patients. Inclusion criteria

- Good general and oral health.
- Total absence of any contraindication for rehabilitation with osseointegrated implants.
- Good disposition and capacity for understanding and following instructions strictly.
- Young adults between the ages of 20 and 45.
- Patients with collapsed edentulous areas, with sufficient

remaining bone to permit the initial stability of the implanted structure, or teeth with signs of extraction and bone loss, without any pathologies or infectious processes.

Five patients made up the selected group with 7 "study sites" into which an implant was inserted with its respective membrane.

Site 1- Socket tooth 19; Site 2- Socket tooth 12; Site 3- Socket tooth 8; Site 4- Alveolar ridge in site of tooth 7; Site 5 - Alveolar ridge in site of tooth 8; Site 6 - Alveolar ridge in site of tooth 9; Site 7 - Alveolar ridge in site of tooth 10.

In Sites 1-2 and 3, implants were immediately inserted. Sites 5-6 and 7 related to the same patient.

For this study an aluminum oxide membrane was used as a physical barrier,²⁵ mean thickness (0.06 mm). This was kept in place for 14 weeks.

Clinical study

With regard to the sockets, the following measurements were taken:

Height of the vestibular plate at mean portion. Height of the palatal or lingual plate at mean portion, width of socket at mean portion, width of socket at mesial portion and width of socket at distal portion. In collapsed ridges where the plates could not be distinguished, the measurements were taken once the bony bed that was to house the implant had been made, and these were the following:

Height of the vestibular ridge of the bony bed at mean portion, height of the palatal or lingual ridge of the bony bed at mean portion, width of the ridge at mesial portion and width of the ridge at distal portion. For registering height, two sterile metallic rulers were used. One of them was positioned at the points previously indicated up to an imaginary line that corresponded with the projection of the occlusal plane. For this, another sterile ruler was used in a horizontal direction as a reference. This ruler was put against the incisal borders or occlusal faces of the teeth by the gap. In this way the height was registered in a vertical sense, perpendicular to the reference point.

The thickness dimensions were registered with a metal calibrator.

These measurements were taken at the time of the first surgery before the placement of the implants and membranes, as well as at the second intervention when the membrane was removed at 14 weeks ([Fig.1](#)).

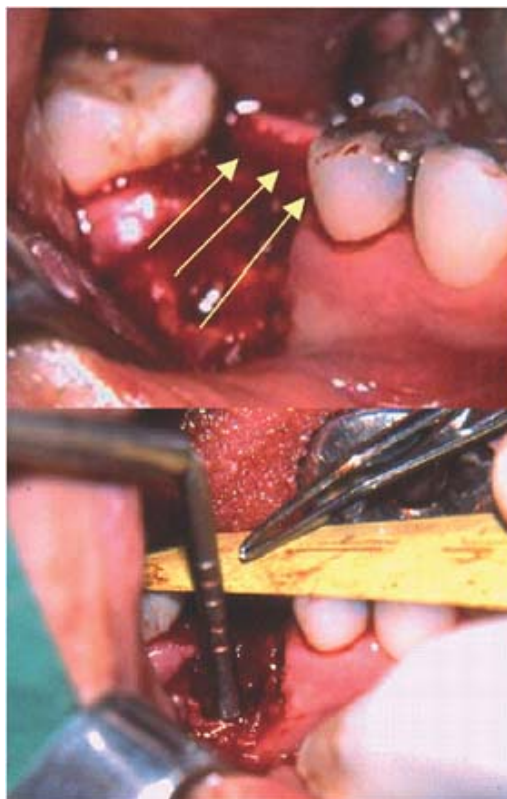


Figura 1. Medición de las dimensiones del reborde alveolar óseo.
Figure 1. Measurement of the dimensions of the bony alveolar ridge.

Panoramic and retroalveolar radiographies were used before the first surgical intervention, with data of not more than a month before the date of the surgical intervention, and once the membranes had been removed at 14 weeks in order to measure density and bone height.

Surgical act

In the pre-operative period, Amoxicillin of 750mg was prescribed, 1 tablet 6 hours before the intervention, and Betamethasone 0.6 mg, 5 tablets half an hour before the surgery. Infiltrative anesthetic technique, Mepivacaine at 2%. Tooth extractions were carried out in the immediate implant cases. Then, the two cases in the study were dealt with indistinctly in the following fashion:

Mucoperiosteal crevicular flap with two vertical incisions, from the mucogingival union to the base of the papillae at the edge of the gap (mesially and distally). Making of the bony bed in the collapsed ridge or socket according to the case, insertion of the implant into the surgical bed following the conventional technique. Partial sectioning of the periosteum from the base of the flap in order to give more elasticity. Handling, shaping and installing the membrane, ensuring the bone is completely sealed with the membrane. Suturing, leaving the membrane totally covered.

All the patients were given postoperative medication with Amoxicillin 750 mg every 8 hours for 7 days, analgesics, of choice Nimesulide (Aldoron[®]) 100 mg 1 tablet every 12 hours depending on the pain, chlorhexidine gluconate rinse at 0.12% twice a day for 14 days. In membrane exposure cases the rinse was continued for longer.

Revulsive treatment was given for controlling the edema and instructions were given to the patient not to speak or gesticulate much. When wishing to communicate they had to do this in writing for at least the first week. Finally, the evaluations were carried out the second day after the surgery, then weekly during the first month, and every two weeks for the remaining months. The patients with exposed membranes were followed weekly. (Fig. 2)

Results

Clinical results. After the first intervention, there was only slight inflammation that did not continue for more than three days. As there were no major complications, the patients continued using Chlorhexidine (Perio-Aid®) for the 15 days indicated. In 3 patients (Sites N°1, N°2, and N°4) there was premature exposure. Sites N°1 and N°4 were those with the greatest exposure, and as there were no associated signs or symptoms of infection, the patients were instructed to use additional antiseptic and to maintain good plaque control for the remainder of the study. Due to this, the barrier did not have to be removed before the stipulated time.

At 14 weeks the membranes were removed. Those with premature exposure were easily removed and large flaps were not required. Under the more exposed membranes and in relation with the inside area (over the defect) granulation tissue could be observed but only on the surface, as on carrying out the second clinical measurements the presence of newly formed tissue could be observed underneath. Site N°2, despite slight exposure, did not show these characteristics as when the membrane was removed, tissue with a periosteal appearance could be observed with new bone underneath. In the remaining Sites without exposure (N°3, N°5, N°6 and N°7), the same pattern was repeated on removing the membrane, as tissue that was more or less like periosteum could be observed that was firm and thick, with a transparent appearance, and which was in the process of maturing.

In general, all the new clinical measurements revealed new bone tissue formation, with the exception of Site N°1 that had vestibular and palatal height that was slightly lower. However, the dimensions in relation to the width of the ridge increased favorably, especially mesially and distally.

Dehiscences concerning the implants were noticeably repaired in most cases, with the exception of Site N°1, as the vestibular defect remained.

A special mention should be made of Site N°4 that initially had a very collapsed ridge and premature membrane exposure. The recovery of the ridge dimensions, especially of the mean, mesial and distal widths in this site was noteworthy.

Tables 1 and 2 give a summary of the clinical measurements taken before and after the placement of membranes and implants, as well as the millimeters gained during the study period.

Table 1. Pre- and post clinical measurement

	Height Vestibular (mm)		Height Palatal or L (mm)		Width Mean (mm)		Width Mesial (mm)		Width Distal (mm)	
	Pre	Post	Pre	Post	Pre	Post	Pre	Post	Pre	Post
	Site 1	14,5	15	10,5	11	10,1	11	4,9	8	5,3
Site 2	5,5	5	9	9	9,5	11	9	12	10,5	12
Site 3	13	12	10,5	10	7,1	8	10	11	9	11
Site 4	11,5	9	9	8	1,5	5,6	2,5	5,5	5,5	5,5
Site 5	14,5	13	10	10	3,4	4,8	3	4	2	4
Site 6	14,5	12,5	12,5	11	2,1	5,4	2	2	2,5	3
Site 7	13	12,5	11	9,8	5,3	5,7	5,4	6	5,5	6,5

Table 2. MM of bone gain at 14 weeks

	Height Vestibular (mm)	Height Palatal or L (mm)	Width Mean (mm)	Width Mesial (mm)	Width Distal (mm)
Site 1	-0,5	-0,5	0,9	3,1	0,7
Site 2	0,5	0	1,5	3	1,5
Site 3	1	0,5	0,9	1	2
Site 4	2,5	1	4,1	3	0
Site 5	1,5	0	1,4	1	2
Site 6	2	1,5	3,3	0	0,5
Site 7	0,5	1,2	0,4	0,6	1
Average	1	0,5	1,7	1,6	1,1

The clinical results are reflected in the average mm measurement in all the sites, which were favorable. A special

mentionshould be made of the general recovery of the medial and mesial aspects, with anaverage of 1.7 mm and 1.6 mmrespectively (Figs. 3 and4).

Statistical analysis

The clinical results were subjected to astatistical t-Student analysis for paired samples. This test was chosen becauseit allows the comparison of two values, before and after, in the sameobservation unit.

The results of the pvalue for the differentsites are registered in [table 3](#).

Tabla 3. Resultados del valor "p" para los distintos sitios

	A (mm)	D (mm)	Variation (mm)	P-value (mm)
AV	12,357	11,286	1,071	0,032
AP	10,357	9,829	0,529	0,105
AN_M	5,571	7,357	1,786	0,014
AN_ME	5,257	6,929	1,671	0,015
AN_D	5,757	6,857	1,100	0,009

AV_A = Average Vestibular Height, Before; AV_D = Average Vestibular Height, After;
AP_A = Average Palatal Height, Before; AP_D = Average Palatal Height, After; AN_M_A =
Average Mean Width, Before; AN_M_D = Average Mean Width, After; AN_ME_A =
Average Mesial Width, Before; AN_ME_D = Average Mesial Width, After; AN_D_A =
Average Distal Width Distal, Before; AN_D_D = Average Distal Width, After.

The results of the statistical analysis revealthat the changes in height and thickness of the ridge, before and after membranereplacement, are statistically significant in all the parameters evaluated, withthe exception of the palatal Height parameter that had a final p-value that wasmore than 0.05.

Discussion

For our study we used aluminum oxide membrane,which unlike other membranes allows maintaining the space underneath without anygraft material, for repairing mainly periimplant bone defects and for recoveringand maintaining the dimensions of the alveolar ridge.

Our study period was limited to 14 weeks. Afterthis period the new height and thickness of the ridges was recorded. Membraneremoval in this period and not afterwards, could encourage the bone tissue thathas formed to mature, as the membrane used is impermeable and nutrients are notable to pass through to the reparation area. It is the periosteum itself thathas to encourage this process once the barrier has been removed. The resultsreveal on average a greater amount of bone tissue in the parameters evaluated.Palatal height was the only parameter evaluated that did not have astatistically significant result. In spite of this, the values of the secondmeasurements of this parameter gave a final positive result. That is to say, again in mm was obtained, but to a lesser extent than in the rest.

The difference in the results regarding palataland vestibular height should not be surprising if we take into considerationthat, in general, dehiscences arise in the vestibular area. On the other hand,numerous studies carried out previously¹⁸ have attributed to themembranes used for GTR, a greater ability for alveolar ridge recovery in ahorizontal sense than in a vertical sense, mainly due to the tendency of theseto collapse, as a result of pressure from soft tissues.

The membrane used in this study showed no signof collapse and in all cases the results were favorable. However, given the factthat a medium thickness membrane was used, which is not usually indicated for aconsiderable height increases, this gain was achieved and a large spaceunderneath was avoided, particularly heightwise, on being adapted to the sitesin the study. This could have been the motive for the later height measurementsbeing clinically less significant.

Site N°1 that corresponded to the socket oftooth 19, was the only site situated in the mandible and the only site to sufferheight loss, vestibular as well as palatal. The type of irrigation in themandible and the design of the flap (Newman) could explain in part these results.Vascular supply to the mandible depends principally on soft tissue supply,particularly from the periosteum, which on being sectioned from its base couldlimit part of the irrigation to the area, hampering the osteogenesis process.²⁴⁻²⁶In this site in particular, we did not consider premature membrane exposure onits own, as a reason behind the loss in bone height, given the very good resultsin other sites, which similarly suffered exposures, but were situated in themaxilla unlike in this case.

Premature exposure of the membrane in Sites 1,2and 4 could be related to more than one factor. The patients in Sites 1 and 4were individuals with jobs that required them to communicate verbally(kindergarten teacher and Vet respectively). This could have favored thetraction of the flap with the periosteum that was sectioned

practically at its base. On the other hand, the implant situated in Site N°1 was immediate, and this made it necessary to section the periosteum more deeply in order to give the flap greater elasticity and to cover the implant and the membrane of a wide socket in the molar region.

Perhaps the surgical protocol could be slightly modified, and a prudent post-extraction time period could be observed, until a sufficient amount of soft tissue appeared that would enable us to avoid sectioning the periosteum and to suture with less tension.

On the other hand, in spite of the implant in Site 4 being immediate, that is, it had sufficient soft tissue to enable good primary closure, the membrane became exposed prematurely. In spite of this, the results of the second measurements in this site were noteworthy. Premature exposure of the membrane in this case did not lead to any complication or bone loss as occurred in the study of other membranes with premature exposure that led to infection and bone loss.²²⁻²³⁻²⁵ The use of chlorhexidine rinses in patients with premature exposure without doubt contributed to maintaining good plaque control and any infectious complications that would have hastened the removal of the membrane were avoided.

Site N°3 did not suffer membrane exposure despite having an immediate implant, and in the radiographic evaluation an intact alveolar bone crest could be observed at three and a half months. That is to say, the aluminum membrane also served to maintain the original dimensions of the border, and even to increase them, and an average mm gain was obtained in all the parameters studied. This fact is of great importance if we consider the future rehabilitation of the site, as the membrane encourages bone regeneration in the area and it halts one of the most trivial problems of dental extractions, which is bone resorption.

Conclusions

Aluminum oxide membrane is capable of maintaining extra-skeletal tissue isolated from the bone repair site, and it avoids the migration of epithelial cells and of connective tissue. Even in the cases where the membrane became exposed, dehiscences were repaired on installing the implants, which led to an increase in the vertical (except in site N°1) as well as horizontal dimension of the ridge, despite not using any graft material underneath, and the space created was filled by the blood clot, which hypothetically favors the concentration of growth factors and therefore, of osteogenesis.

Suggestions

- Aluminum oxide membranes should be used in a larger number of patients.
- Histological studies should be carried out of the tissue formed directly underneath the membrane.
- Microbiological studies should be carried out on the adherence of bacteria to the membrane.
- Finally we would like to suggest waiting for mucosal closure before placing the implants and membranes once the extraction has been carried out. In this way, primary closure tension can be avoided and the sectioning of the periosteum.

Acknowledgments

To the company Demac for donating Allumina[®] membrane.

To Doctor Benjamín Martínez, ex-pathologist of the "Universidad de Chile" and staff member of the "Bioestadística de la Universidad Mayor" for his assessment in the statistical analysis.

Correspondence:

Dr. Mario Isa Majluf
Apdoquindo 4100 dpto. 601 Las Condes
Santiago de Chile, Chile
Email: Isamohor@ctcinternet.cl

Recibido: 16.01.06

Aceptado: 01.06.07

References

1. Christop y cols. Single stage surgery combining transmucosal implant placement with guided bone regeneration and bioresorbable materials. *Clin Oral Impl Res* 2001;12:9-18. [[Links](#)]
2. Otti P, y cols. The Procera AllCeram Sistem. *Int J Periodontics Restorative dent* 2000; 20:151-61. [[Links](#)]
3. Malmquist J, y cols. Successful implant restoration with the use of barrier membranes. *J Oral Maxillofac Surg* 1999;57:1114-6. [[Links](#)]
4. Dupoirieux L, y cols. Comparative study of three different membranes for guided bone regeneration of rat cranial defects. *Int J Maxillofac Surg* 2001;30:58- 62. [[Links](#)]
5. Dörfer C, y cols. Regenerative periodontal surgery in interproximal intrabony defects with biodegradable barriers. *J Clin Periodontol* 2000;27:162-8. [[Links](#)]
6. Zitzmann N, y cols. Long-term results of implants treated with guided bone regeneration: A 5-year prospective study. *Int J Oral Maxillofac Impl* 2001;16:355- 66. [[Links](#)]
7. Karapataki S, y cols. Healing following GTR treatment of intrabony defects distal to mandibular 2nd molars using resorbable and non-resorbable barriers. *J Clin Periodontol* 2000;27:333-40. [[Links](#)]
8. Cruz M, y cols. *Utilicao da alumina como membrana na Regeneracao Guiada dos Tecidos*. Odontologico Moderno Sao Paulo 1993;20:6-13. [[Links](#)]
9. Yasonuri S, y cols. Aumento del reborde alveolar con redes de titanio y hueso autógeno. *Oral Surg Oral Med Oral Pathol* 2000;89:268-70. [[Links](#)]
10. Nociti F, y cols. Absorbable versus non-absorbable membranes and bone grafts in the treatment of ligature-induced peri-implantitis defects in dogs: A histometric investigation. *Int J Oral Maxillofac Impl* 2001;16:646-52. [[Links](#)]
11. Barry K, y cols. Extraction site reconstruction for alveolar ridge preservation. Part 1: Rationale and material selection. *Journal of Oral Implantology* 2001;27:187-93. [[Links](#)]
12. Barry K,y cols. Extraction site reconstruction for alveolar ridge preservation. Part 2: Membrane-Assisted surgical technique. *Journal of Oral Implantology* 2001;27:194-7. [[Links](#)]
13. Bunyaratavej P, y cols. Collagen Membranes: A Review. *J Periodontol* 2001;72:215-29. [[Links](#)]
14. Celleti R, y cols. Guided tissue regeneration around dental implants in immediate extraction sockets: Comparison of e-PTFE and a new titanium membrane. *Int Periodont Rest Dent* 1994;14:243-53. [[Links](#)]
15. Mohamed A, y cols. Immediate implants in fresh posterior extraccion sockets: Report of two cases. *J Oral Implantol* 2001; 2:123-6. [[Links](#)]
16. Marlin E, Gher et. al. Combined dental implant and guided tissue regeneration therapy in humans. *Int J Periodont Rest Dent* 1994;14:333-47. [[Links](#)]
17. Nociti F, y cols. Absorbable versus nonabsorbable membranes and bone grafts in the treatment of ligature-induced periimplantitis defects in dogs. *Clin Oral Impl Rest* 2001;12:115-20. [[Links](#)]
18. Massimo M, y cols. Vertical ridge augmentation using a membrane technique associated with osseointegrated implants. *Int J Periodont Rest Dent* 1994;14:497-511. [[Links](#)]
19. Diès F, y cols. Bone regeneration in extraction sites after imediate placement of an e-PTFE membrane with or without a biomaterial. *Clin Oral Impl Res* 1996; 7:277-85. [[Links](#)]
20. Von Arx, y cols. Lateral ridge augmentation using difeerent bone fillers and barriers membrane application. *Clin Oral Impl Res* 2001;12:260- 9. [[Links](#)]
21. Buser D, y cols. Regeneration and enlargement of jaw bone using guided tissue regeneration. *Clin Oral Impl Rest* 1990;1:22-32. [[Links](#)]
22. Gher M, y cols. Bone grafting and guided bone regeneration for immediate dental implants in humans. *J Periodontol* 1994;65:881-91. [[Links](#)]

23. Wang H; y cols. Adherence of oral microorganisms to guided tissue membranes: In vitro study. *J Periodontol* 1994;65:211-8. [[Links](#)]
24. Testut L, Jacob O. *Tratado de Anatomía Topográfica con aplicaciones medicoquirúrgicas*. 1964:207. [[Links](#)]
25. Isa M y col. Uso de la membrana Allumina® en la preservación del reborde alveolar postextracción. *Magazine Internacional College of Dentists Section Four* 2001;8:61-8. [[Links](#)]
26. Walter JB, Hamilton MC, Israel MS. *Principles of pathology for dental students*. (4a.ed). Edinburgh: Churchill Livingstone, 1981;p.p.570. [[Links](#)]
27. Guitián P, y cols. *Preparación de cavidades por microabrasión*. Facultad de Medicina y Odontología de la universidad Santiago de Compostela. <http://www.infomed.es/mode/mode97/mesa3.html>. [[Links](#)]
28. Peterson A, y cols. *Avaliacao clínica da técnica de regeneracao tecidual guiada utilizando uma barreira de óxido de aluminio no tratamento de lesoes de furca classe II em humanos: relato de 12 casos*. Proyecto fundo de incentivo a pesquisa (FIP), nº 94/022 Pontificia Universidad de Católica de Minas Gerais. [[Links](#)]
29. Wilson T, y cols. *Implants placed in immediate extraccion sites: a report of histologic and histometric analysis of human biopsies*. *Int J Oral Maxillofac Impl* 1998;13:333-41. [[Links](#)]
30. Steven G, Lewis. *Sisitema de implantes Branemark*. Editorial Espax S.A. 1991; p.p. 1-10. [[Links](#)]
31. Nyman, y cols. New attachment following surgical treatment of human periodontal disease. *J Clin Periodontol* 1982;9:290-6. [[Links](#)]
32. Takashi T, y cols. Migration of osteoblastic cells on various guided bone regeneration membranes. *Clin Oral Impl Res* 2001;12:332-8. [[Links](#)]
33. Rocuzzo M, y cols. Comparative study of a bioresorbable and a nonbioresorbable membrane in treatment of human bucal gingival recessions. *J Periodontol* 1996;67:7-14. [[Links](#)]
34. Piattelli A, y cols. Histological evaluation of bone reaction to aluminium oxide dental implants in man. *Biomaterials* 1996;17:711-4. [[Links](#)]

© 2010 Ediciones Ergon, S. A.

C/ Arboleda, 1
28220 Majadahonda
Madrid
Tlf.: 91 636 29 30
Fax: 91 636 29 31



lucia.agudelo@ergon.es